UCDAVIS
VETERINARY MEDICINE
California Animal Health & Food Safety Laboratory System
105 W. Central Avenue
San Bernardino, CA 92408-2113
www.cahfs.vetmed.ucdavis.edu

CAHFS Accession #: S2110265

FINAL REPORT

Ref.#: Medina Spirit

Coordinator: Javier Asin Ros, DVM, PhD, Dipl. ECVP

E-Signed and Authorized by: Asin Ros, Javier on 2/10/2022 1:26:54PM

Email To:
Baker, Rita L
RitaB@chrb.ca.gov

Incident Track:
SANTA ANITA RACETRACK
285 West Huntington Road,
Arcadia CA 91007
Los Angeles County

This report supersedes all previous reports for this case

Date Collected: 12/06/2021 **Date Received:** 12/06/2021

Comments: CHRB

Case Contacts

Submitter	Pattio, Nolton	[redacted]	[redacted]	Los Alamitos	CA	90720
Bill To	CALIFORNIA HORSE RACING BOARD	916-263-6000	1010 Hurley Way Suite 300	Sacramento	CA	95825
Owner	Zedan Racing Stables		[redacted]			
Report To	UZAL, FRANCISCO	[redacted]	Cahfsl	San Bernardino	CA	92408
Report To	Baker, Rita L		1010 Hurley Way, Suite #300	Sacramento	CA	95825
Report To	Hill, Ashley		Cahfs - 620 West Health Science	Davis	CA	95616
Attending Vet	Bohannon, Laurie		[redacted]	Arcadia	CA	91006
Trainer	BAFFERT, BOB		[redacted]	La Canada Flint	CA	91011

CHRB - Related Information

Horse's Name:	**Medina Spirit**	Human Injury?	No
Tattoo:	MC# [redacted]	Death Related to:	Training
Age:	3.00 Years	Track Surface:	Dirt
Gender:	Male	Location on Track:	7/8th pole
Taxonomy:	Thoroughbred Horse	Insured?	Y

Medications: Lasix (Furosemide);

Laboratory Findings/Diagnosis

A Thoroughbred racehorse ("Medina Spirit") that died suddenly while working

Cause of death: undetermined; sudden cardiorespiratory arrest/ cardiac failure suspected

Main gross/microscopic findings:
1. Heart (see Histology for details and specific locations)
  1a. Hemorrhages, minimal
  1b. Very rare mononuclear infiltrates
  1c. Hypercontraction bands, subendocardial, left ventricular papillary muscles, minimal
2. Lungs (see gross photos at the end of the report):
  2a. Congestion and edema, diffuse, severe, with rare, multifocal, acute alveolar hemorrhages

2b. Pleural fibrosis/plaque, focal, mild
2c. Hemosiderosis, subpleural, focal, minimal
2d. Venous remodeling, multifocal, mild
3. Spleen: Congestion, diffuse, severe
4. Multiple organs (see Gross Observations & Histology): Congestion, petechiae, microscopic hemorrhages

Musculoskeletal examination of limbs (per Dr. M. Samol):
1. Fetlocks and elbows: Mild to moderate degenerative joint disease

Ancillary test results:
1. No aerobic bacteria isolated; liver, lung
2. Negative Salmonella sp screen; liver
3. No parasite eggs detected; feces
4. Negative anticoagulant rodenticides screen; liver
5. Negative GCMS & LCMS screen; liver
6. Mineral concentrations within acceptable/non-diagnostic ranges; liver
7. T4 (thyroxine) - immulite, <0.05 ug/dL [RI 1-3]; blood (per Cornell Univ. AHDC; see attached report)
8. Furosemide and Omeprazole Sulfide detected at screening; blood, urine (per EACL; see attached report)

Case Summary

12-07-21: The cause of death of this horse was not evident on gross examination. Main necropsy findings were swollen and wet lungs, abundant foam in the trachea, splenomegaly, and congestion and petechiae in several locations. These findings are common in racehorses with sudden death, and are compatible with, but not specific for, cardiac failure. Histology will also help to determine if there is a degree of pulmonary hemorrhage. A comprehensive diagnostic work up is ongoing. More results will follow in subsequent versions of this report. Please, do not hesitate to contact us if you have any question about this case.

02-01-22: The definitive cause of death of this horse was not determined after post-mortem examination and extensive laboratory testing.
The most remarkable gross and microscopic changes were pulmonary congestion and edema, with milder hemorrhage. There were also congestion and small hemorrhages in multiple organs. No significant evidence of prior episodes of pulmonary hemorrhage other than a single and mild focus of hemosiderosis was observed.
Detailed microscopic examination of the heart revealed minimal changes in the myocardium (hypercontraction bands). Although the significance of this finding remains undetermined, it is likely incidental because of the limited extension and severity, and also because similar changes have been seen before in horses dying of non-cardiac related causes (e.g. euthanasia). In addition, mild remodeling (thickening of the adventitia) of the intra-pulmonary veins was observed. This is also likely an incidental finding.
Extensive toxicologic testing using multiple samples obtained at necropsy was unrewarding.
Considered altogether, the results of the post-mortem examination, histopathology, and ancillary testing, are supportive of a sudden cardiorespiratory arrest as it may occur with acute cardiac failure. A defect in the cardiac conduction system should be considered as a possible cause of cardiac failure.
The four legs were also fully examined and revealed mild to moderate degenerative joint disease of the four fetlocks and both elbows. These changes are considered incidental and unrelated to the cause of death of this horse.
A set of samples (left ventricle myocardium and hair roots) were sent to the Veterinary Genetics Laboratory of UC Davis and to the University of Minnesota (per CHRB request) for research purposes.
This concludes testing in this case.

References
-Diab SS, Poppenga R, Uzal FA. Sudden death in racehorses: postmortem examination protocol. J Vet Diagn Invest. 2017 Jul;29:442-449. doi: 10.1177/1040638716687004

02-10-22: Case materials were sent for peer review to Drs. Grant Maxie (University of Guelph) and Laura Kennedy (University of Kentucky) on 02-01-22. Their review reports (attached) concurred with our findings.

Clinical History

Sudden death while working.

Gross Observations

Necropsy of a 525 kg, bay, Thoroughbred cryptorchid colt with microchip #[redacted], no lip tattoo, a right hind limb white pastern that is higher in the back, and a small star on the forehead, began at 11.45 am, December 6, 2021.

Carcass is in good nutritional condition, with scant fat reserves and prominent musculature, and in mild state of postmortem decomposition.

There are blue stained tape bandages at the level of both fetlock joints. The distal end of the four limbs is soiled with dirt. There are scant, soft feces oozing from the anus. There are multifocal, 1 to 3 cm scratches on the upper left eyelid and the adjacent skin of the forehead. The skin of the left side of the head and neck is abraded and with dry blood.

Lungs are diffusely swollen, wet, and rubbery, and there are multifocal pleural to subpleural petechiae on all lung lobes. There is a regionally extensive, ~6 cm area of mild pleural fibrosis on the cranioventral aspect of the left caudal lung lobe. The dorsal aspect of both caudal lobes is diffusely gray. At cut section, the pulmonary parenchyma oozes scant blood and foam. There is abundant, pinkish, stable foam in the trachea. The tracheobronchial lymph nodes have dark-red discoloration. There is a prominent thymic remnant with multifocal petechiae. The heart is examined and sampled for histological evaluation as per cardiac necropsy protocol (Diab et al, 2017), and there are no gross abnormalities other than a few petechiae on the epicardium.

The spleen is markedly enlarged, meaty, and oozes thick blood at cut section. There are rare, fibrous tags on the capsule of the diaphragmatic aspect of the right lobe of the liver. The kidneys have marked, bilateral, corticomedullary dark-red discoloration (congestion). The urinary bladder contains ~ 250 mL of yellowish urine with very scant, sandy sludge. There is an atrophic, undescended testicle in the retroperitoneal space. Stomach contains moist grain and forage, and the mucosa of the glandular portion is mildly congested. Intestinal contents range from watery and light brown in the small intestine, to greenish, soft and with grain and forage in the colon and cecum; mucosal surfaces are unremarkable. There is a moderate amount of soft feces in the small colon and rectum.

The head is sagitally sectioned for brain extraction and skull and brain examination. There are no gross abnormalities to note.

All else is unremarkable*

*The vertebral column and four limbs have been saved for examination at a later stage.

Addendum (12-8-21): The entire vertebral column is sagitally sectioned for spinal cord extraction and spinal canal and vetebrae examination. There are no significant gross changes to note. See musculoskeletal examination of the limbs below at "CHRB Musculoskeletal".

Addendum (1-23-22): The fetlock joints with the blue bandages referred to above were the hindlimbs fetlock joints.

Addendum (1-25-22): A set of gross photos is provided at the end of the report.

CHRB Musculoskeletal

Musculoskeletal examination per Monika A Samol, DVM, MRCVS, Musculoskeletal Pathology Fellow

All 4 limbs were removed and fully examined. The following changes were noted:

LEFT FORELIMB

A- ELBOW

1. Severe scoring lines of distal articular surface of humerus and proximal articular surface of radius
2. Linear defect of the cartilage of the humeral lateral condyle/capitulum - the sagittal defect is approximately 0.7 cm long, and it is located roughly adjacent the trochlea in the cranial third of the articular surface

B- FETLOCK

a) Proximal sesamoid bones (PSBs)

1. Moderate to severe, biaxial apical enthesophytosis accompanied by dark blue-/grey-tinged discoloration of the cartilage- the lateral PSB is slightly more affected than the medial
2. Mild, biaxial basilar enthesophytosis accompanied by dark blue-/grey-tinged discoloration of the cartilage along the basilar articular margin
3. Mild, biaxial, focally extensive dark blue-/grey-tinged discoloration of the cartilage along the abaxial articular margins

b) 3rd Metacarpus (MCIII)

1. Moderate, biaxial palmar osteochondral disease (POD) with focally extensive cartilage fibrillation, flattening, and subchondral bone discoloration visible through the cartilage as a dark blue, ellipsoidal focus

c) Soft tissues

1. Moderate synovial thickening accompanied by red discoloration suggestive of proliferative synovitis

RIGHT FORELIMB

A- ELBOW

1. Mild to moderate scoring lines of distal articular surface of humerus and proximal articular surface of radius
2. Linear defect of the cartilage of the humeral lateral condyle/capitulum - the sagittal defect is superficial, approximately 1 cm long, and it is located roughly adjacent the trochlea in the cranial third of the articular surface. The surrounding cartilage is discolored (pink), its surface is slightly irregular, and the superficial layer feels soft on palpation

B- FETLOCK

a) PSBs

1. Mild to moderate, biaxial apical enthesophytosis accompanied by dark blue-/grey-tinged discoloration of the cartilage- the lateral PSB is slightly more affected than the medial
2. Mild, biaxial basilar enthesophytosis accompanied by dark blue-/grey-tinged discoloration of the cartilage along the basilar articular margin
3. Mild, biaxial, focally extensive dark blue-/grey-tinged discoloration of the cartilage along the abaxial articular margins

b) MCIII

1. Moderate, biaxial POD with focally extensive cartilage fibrillation, flattening, and subchondral bone discoloration visible through the cartilage as a dark blue, ellipsoidal focus

c) Soft tissues

1. Moderate synovial thickening accompanied by red discoloration (interpreted as proliferative synovitis)

LEFT AND RIGHT HINDLIMBS

A- FETLOCKS

a) PSBs

1. Moderate biaxial basilar and apical enthesophytosis accompanied by dark blue-/grey-tinged discoloration of the cartilage along the basilar articular margin
2. Mild, biaxial, focally extensive dark blue-/grey-tinged cartilage discoloration with superficial cartilage loss within the abaxial articular margin of the medial PSB

b) 3rd Metatarsus (MTIII)

1. Moderate, biaxial plantar osteochondral disease (POD) with subchondral bone discoloration visible through slightly flattened

cartilage as a dark blue round focus (medial condyles are more severely affected)- the cross sections of affected region in medial condyles revealed distinct focus of yellow discoloration in the subchondral bone surrounded by brown and dark red rim

c) Proximal phalanx - P1

1. Mild, focal, superficial cartilage loss of the dorsomedial margin of the proximal articular surface
2. Mild to moderate, focal, dark blue discoloration of the intermediate groove cartilage (plantar aspect)

d) Soft tissues

1. Mild to moderate synovial thickening accompanied by red discoloration suggestive of proliferative synovitis

For better visualization of the findings described above please refer to attached photographs.

No other gross lesions/ abnormalities were identified in other examined structures of the limbs.

Bacteriology

BACTERIAL AEROBIC CULTURE

Animal/Source	Specimen	Specimen Type	Results
Medina Spirit	Medina Spirit	Liver Swab	No growth after 48 hours
Medina Spirit	Medina Spirit	Lung Swab	No growth after 48 hours

Salmonella RT PCR Screen & culture

Animal/Source	Specimen	Specimen Type	Results
Medina Spirit	Medina Spirit	Liver Swab	Negative

Histology

Sections of heart (15 sections from 11 different regions per cardiac necropsy protocol [Diab et al, 2017] including: 1. Right ventricular free wall, with the right atrial wall, the right coronary artery, and the parietal cusp of the tricuspid valve; 2. Pulmonay artery semilunar valve with the right ventricular outflow tract and the pulmonary artery; 3. Right atrial appendage; 4. Sinoatrial node region [three sections, A-C]; 5. Left atrial appendage; 6. Left ventricular free wall, left atrial wall, left coronary artery, and the parietal cusp of the left atrioventricular valve; 7. Left ventricular papillary muscle 1/2 [examined also with PTAH stain for highlighting hypercontraction bands] ; 8. Left ventricular papillary muscle 2/2 [examined also with PTAH stain for highlighting hypercontraction bands]; 9. Atrioventricular node region [three sections, A-C]; 10. Interventricular septum; and 11. Aortic semilunar valve, aorta, and left ventricular outflow tract), lungs (5 sections examined, including the four lung lobes and one additional section [region of focal pleural fibrosis detected grossly]; sections examined also with Masson trichrome for collagen, Verhoeff for elastic fibers, Perls Prussian blue for iron, PAS for mucus, and PTAH for fibrin stains), fat, lymph nodes (several), thymus, liver, pancreas, thyroid gland, testicles (scrotal and undescended), skeletal muscle, diaphragm, epiglottis, adrenal gland, tongue, esophagus, urinary bladder, abdominal aorta, spleen, kidneys, deferent ducts, stomach, small intestine, colon, cecum, haired skin, trachea, and brain (10 sections including basal nuclei, frontal cortex, thalamus and hypothalamus, hippocampus, choroid plexus, parietal cortex, midbrain, cerebellum, pons, and medulla), pituitary gland, and spinal cord (9 cross and longitudinal representative sections of cervical, thoracic and lumbosacral segments) are examined with changes summarized (slides were reviewed by two pathologists: Javier Asin Ros, DVM, PhD, Dipl ECVP & Francisco A. Uzal, DVM, MSc, PhD, DACVP):

HEART
-Right coronary artery (region 1): There are minimal hemorrhages in the outer media and adventitia. There are two minimal aggregates of lymphocytes and plasma cells close to some small nerve bundles in the epicardial fat.
-Myocardium close to the sinoatrial node (region 4, section B): There is a minimal, loose aggregate of lymphocytes, histiocytes, and rare neutrophils in the interstitium.
-Left atrial appendage (region 5): There is a minimal perivascular aggregate of lymphocytes, histiocytes, and plasma cells.
-Left ventricular papillary muscles (regions 7 and 8): There are minimal, eosinophilic hypercontraction bands in a few, immediately subendocardial cardiomyocytes.
-Aorta (region 11): There are regionally extensive, moderate hemorrhages in the outer media and adventitia that spread to the adjacent fat and small nerve bundles.

LUNG
There is diffuse and marked congestion of the septal capillaries and medium sized vessels in all the sections examined, multifocal areas of alveolar edema, and less, multifocal to coalescing areas of alveolar hemorrhage. The lumen of small- to medium-sized airways contains rare aggregates of mucus, sloughed cells, faintly eosinophilic globules, and rare erythrocytes. There is one section where the alveolar lumina are regionally and mildly overinflated and the septal vessels are less congested and contain rare, eosinophilic globules (PTAH negative, slightly PAS positive). Multifocally, small- and medium-sized vessels close to the bronchioles (bronchial and pulmonary arteries) are surrounded by loose collagen; rarely, there are small-caliber, thin-walled, congested vessels embedded in this collagen and adjacent to the adventitia of the mentioned vessels. The pulmonary veins within the parenchyma have mild thickening of the adventitia. The interlobular septa are occasionally expanded with dilated, blood-filled lymphatics, which also seem to occur below the pleura and adjacent to the airways in some sections. There is a focus with aggregates of hemosiderophages around some vessels and below the pleura. The pleura is regionally expanded by mild fibrosis, with small-caliber, thin-walled vessels just beneath.

THYMUS
There is diffuse congestion and multifocal cortical and medullary hemorrhages.

PANCREAS
There are rare hemorrhages in the interstitium.

LIVER
There is diffuse and moderate congestion in several sections and rare, random, minimal aggregates of lymphocytes, plasma cells, and histiocytes in the sinusoids. There is a small region of capsular fibrosis in one of the sections. In one of the sections, there is a region with rare, lightly eosinophilic globules in the sinusoids.

LYMPH NODES
-Tracheobronchial: There is marked, diffuse congestion and extravased erythrocytes in the sinuses.
-Others: There are rare foci of hemorrhage and mild to moderate lymphoid hyperplasia.

ADRENAL GLAND
There is marked cortical congestion, especially at the level of the zona reticularis.

SPLEEN
There is diffuse and severe congestion of the red pulp that partially effaces the lymphoid follicles of the white pulp.

KIDNEY
There is marked and diffuse cortical and medullary congestion of the interstitial vessels, and rare, minimal interstitial aggregates of lymphocytes and plasma cells. There are rare (<5%) tubules with hypereosinophilic and mildly fragmented epithelial cells in the corticomedullary junction. Diffusely and globally, glomerular capillaries are markedly congested. Focally, less than 10% of the glomeruli have small numbers of lightly eosinophilic globules in the Bowman's space.

STOMACH
There is mild to moderate congestion of the vessels in the lamina propria of the glandular region.

SMALL INTESTINE AND COLON
Small vessels in the lamina propria and submucosa are moderately congested. There are scattered eosinophils in the lamina propria and submucosa of some sections of colon. There are rare ciliated protozoa in the lumen of the colon.

TESTICLES
In the undescended testicle, spermatic tubules are hypocellular and there is no spermatogenesis. There are rare groups of interstitial cells (less numerous compared with the scrotal testicle), and multifocal, small but dense infiltrates of lymphocytes, histiocytes, and less plasma cells in the interstitium. There is a minimal hemorrhage in the interstitium of the scrotal testicle.

SKELETAL MUSCLE
There are rare, minimal hemorrhages in the endomysium and perimysium.

BRAIN
There are rare hemorrhages in the neuropil of the gray matter at the level of the medulla, and one minimal perivascular aggregate of lymphocytes and histiocytes in the choroid plexus.

PITUITARY GLAND
There are rare, loose, minimal, perivascular aggregates of lymphocytes and histiocytes in the neurohypophysis.

SPINAL CORD
There are minimally and unevenly dilated myelin sheaths in the dorsal, ventral, and lateral funiculi of several sections of cervical, thoracic, and lumbosacral spinal cord. In the white matter of the thoracic spinal cord, there is a small vessel packed with intraluminal/circulating lymphocytes, plasma cells, and less neutrophils.

All else is unremarkable.

Parasitology

Test Specific Comments
FECAL EXAM - FLOTATION

* < 10 per slide in a concentration method is consistent with very few eggs present in the sample. >= 10 per slide in a concentration method is consistent with a notable presence of eggs in the sample.
* Fecal flotation requires at least 1g to provide accurate results. It is a qualitative method that concentrates eggs present in the sample to maximize their detection. A Modified McMasters exam, which requires at least 3 g, is recommended for semi-quantitative information about the number of eggs present per gram of feces, which may aid in clinical assessment and treatment decisions. If <3 g is available, a flotation exam is performed.

FECAL EXAM - FLOTATION

Animal/Source	Specimen	Specimen Type	Results
Medina Spirit	Medina Spirit	Feces	No parasite eggs detected

Toxicology

Reporting Limit (Rep. Limit): The lowest routinely quantified concentration of an analyte in a sample. The analyte may be detected, but not quantified, at concentrations below the reporting limit. Sample volumes less than requested might result in reporting limits that are higher than those listed.

The detected liver mineral results are within acceptable or non-diagnostic ranges for this species.

The submitted specimen contained none of the listed anticoagulant rodenticides in a concentration greater than the stated reporting limits.

No compounds of interest were detected in the tested specimen(s) by our gas chromatography - mass spectrometry (GC/MS) and liquid chromatography - mass spectrometry (LC/MS) organic chemical screens. The screens are designed to potentially detect a large number of organic compounds belonging to diverse chemical classes (pesticides, environmental contaminants, drugs and natural products). Control matrices were obtained to compare analytical results with those obtained from the tested specimen. It is important to point out that identifications of compounds by the screens should be considered unconfirmed (they are most likely present as identified, but additional analysis using pure standards would be necessary for confirmation and, when appropriate, quantification). It is also important to know that a negative result does not necessarily preclude the presence of a chemical of concern since the screens are not considered to be comprehensive (there is no single test that can completely rule out the presence of a toxic compound in a tested sample).

Within the limits of the samples tested and the analytical procedures performed, a toxic cause for the described problem was not evident in this case.

Anticoagulants Screen – Quantitated

Animal/Source	Specimen	Specimen Type
Medina Spirit	Medina Spirit	Liver Tissue

Analyte	Result	Units	Rep. Limit	Units
Brodifacoum	Not Detected	ppb	20	ppb
Bromadiolone	Not Detected	ppb	20	ppb
Chlorophacinone	Not Detected	ppb	20	ppb
Coumachlor	Not Detected	ppb	20	ppb

Difethialone	Not Detected	ppb	20	ppb
Diphacinone	Not Detected	ppb	20	ppb
Warfarin	Not Detected	ppb	20	ppb
Difenacoum	Not Detected	ppb	20	ppb

GCMS Screen

Animal/Source	Specimen	Specimen Type
Medina Spirit	Medina Spirit	Liver Tissue

Analyte	Result	Units	Rep. Limit	Units
Negative	See comment under Toxicology	NA	NA	NA

HEAVY METALS- EXTENDED

Animal/Source	Specimen	Specimen Type
Medina Spirit	Medina Spirit	Liver Tissue

Analyte	Result	Units	Rep. Limit	Units
Arsenic	Not Detected	ppm	1	ppm
Barium	Not Detected	ppm	0.1	ppm
Beryllium	Not Detected	ppm	0.02	ppm
Cadmium	1.3	ppm	0.3	ppm
Chromium	Not Detected	ppm	0.3	ppm
Cobalt	Not Detected	ppm	0.3	ppm
Copper	5.4	ppm	0.3	ppm
Iron	150	ppm	1	ppm
Lead	Not Detected	ppm	1	ppm
Manganese	1.7	ppm	0.1	ppm
Mercury	Not Detected	ppm	1	ppm
Molybdenum	0.85	ppm	0.4	ppm
Nickel	Not Detected	ppm	0.6	ppm
Thallium	Not Detected	ppm	1	ppm
Vanadium	Not Detected	ppm	0.3	ppm
Zinc	38	ppm	0.3	ppm

LCMS Screen

Animal/Source	Specimen	Specimen Type
Medina Spirit	Medina Spirit	Liver Tissue

Analyte	Result	Units	Rep. Limit	Units
Negative	See comment under Toxicology	NA	NA	NA

Phone Log

Client Contact	CAHFS Contact	Date and Time	Subject
Dr. Blea	Asin Ros, Javier	12/6/21 3:10 pm	Preliminary gross necropsy report

We VALUE your opinion of our services!

To help us improve, please take a moment to tell us your impression of the services you received.
Please click the link below to be directed to a short survey

CAHFS Client Feedback Survey

Accession# S2110265 (me)
JA
updated 12/9/2021

STATE OF CALIFORNIA
CALIFORNIA HORSE RACING BOARD
NECROPSY SUBMISSION FORM
CHRB-72 (Rev. 06/04)

CAHFS - Davis
620 W. Health Sciences Dr.
Davis, CA 95616
Phone. (530) 752-8709
Fax. (530) 752-7170
chrbnecropsy.davis@ad3.ucdavis.edu

CAHFS - San Bernardino
105 W. Central Ave
San Bernardino, CA 92408
Phone. (909) 383-4287
Fax. (909) 884-5980
chrbnecropsy.sanb@ad3.ucdavis.edu

CAHFS – Tulare
18830 Road 112
Tulare, CA 93274
Phone. (559) 688-7543
Fax. (559) 686-4231
chrbnecropsy.tulare@ad3.ucdavis.edu

Additional necropsy examination(s) that exceed the standard necropsy or equine special necropsy required by and provided through the California Horse Racing Board (CHRB) are the responsibility of the requesting individual (SEE REVERSE SIDE).

When a horse dies or is euthanized and the CHRB Official Veterinarian is not available; the owner's or trainer's attending veterinarian must phone the laboratory within one hour and fax this completed Necropsy Submission Form to the laboratory. A copy of the completed Necropsy Submission Form must be given to the CHRB Official Veterinarian on the official Veterinarian's next scheduled work day.

Delay of necropsy makes some test results questionable in value. A necropsy will not be performed until the following information has been provided:

Dr. Pattio
Name of CHRB Official Veterinarian

Los Alamitos
Track Name

[redacted]
Address

Los Alamitos CA 90720
City State Zip Code

[redacted]
Phone

Medina Spirit
Name of Horse

3 Thoroughbred
Age (years) Breed

intact male No
Sex Castrated

Tattoo ○ Yes# ○ No. Color and markings
MC# [redacted]

Zedan Racing Stables
Name of Owner(s)

[redacted]
Address

City State Zip Code

Phone

Multiple Owner's Yes ○ No ● Unknown ○

Laurie Bohannon (V. Baker)
Name of Attending Veterinarian

[redacted]
Address

Monrovia CA 91016
City State Zip Code

[redacted]
Phone

Bob Baffert
Name of Trainer Trainer License #

[redacted]
Address

Arcadia CA 91066
City State Zip Code

[redacted]
Phone

or Dr. Bohannon
Signature (electronically signed or typed)

Medications: Furosemide (Lasix) 3cc at 5:15

Santa Anita
Track where injury occurred

7/8th Pole
Location on track where injury occurred

Turf ○ Synthetic ○ Main-dirt ● Training-dirt ○

History: Died ● Euthanized ○ Agents used for Euthanasia

12/06/2021
Date of death

07:55 a.m. ● p.m. ○
Time of death

Horse insured: Yes ● No ○ Unknown ○

Human Injury: Yes ○ No ● Unknown ○

Clinical findings & diagnosis:

Horse collapsed following a race training workout ... sudden death

The injury is related to one of the following: Running of the race ○ Training ● Non-exercise related ○ Other ○

Pattio, Nolton
Digitally signed by Nolton Pattio
Date: 2021.12.09 09:27:48 -08'00'
Signature of CHRB Official Veterinarian

12/09/2021
Date

Updated form? No

Accession#_____

STATE OF CALIFORNIA
CALIFORNIA HORSE RACING BOARD
NECROPSY SUBMISSION FORM
CHRB-72 (Rev. 06/04)

REQUEST FOR ADDITIONAL NECROPSY EXAMINATION(S)

I accept financial responsibility for all charges from the California Animal Health and Food Safety Laboratory System for the additional necropsy examination(s) requested below which exceed the standard necropsy or equine special necropsy required by and provided through the California Horse Racing Board.

Additional necropsy examination(s) requested:

Full insurance examination required by insurance company: Yes ◯ No ◯

Hays Companies Insurance
Insurance Company

Address

[redacted]
Phone

City

State

Zip Code

Fax

Additional Owner Information:

Name of Owner

Address

City State Zip Code

Phone

Name of Owner

Address

City State Zip Code

Phone

Print Name

Signature

Date

Cornell University
Animal Health Diagnostic Center
240 Farrier Road, Cornell University, Ithaca, NY 14853
Ph: 607-253-3900 Fax: 607-253-3943
https://ahdc.vet.cornell.edu

Finalized Report

Owner: S2110265

Accession Number: **265746-21**

Cahfs - San Bernardino - (2500)
California An Health And Food Safety Lab
105 W Central Ave
San Bernardino, CA 92408
(909) 383-4287

Sampled: 12/06/2021
Received: 12/09/2021
Finalized: 12/09/2021
Reference Number: S2110265

Endocrinology

Director Dr. Ned J Place - [redacted]

	Test	Result	Reference Interval
1	**S2110265** - Equine Thoroughbred Male		
	Blood, Whole, Clotted		
	T4 (Thyroxine) - Immulite	<0.05 ug/dL	1 - 3

Test Interpretations

T4 (Thyroxine) - Immulite
T4 BASELINE TEST

The concentration of T4 in serum or plasma is within the reference value for normal healthy animals. The concentration of T4 is low or undetectable in hypothyroid animals. Clinically hypothyroid dogs with unexpectedly high T4 concentrations may have autoantibodies against thyroid hormones. The thyroglobulin autoantibody test is suggested in these cases. Hyperthyroid cats will generally have high or high normal T4 results. Free T4 by dialysis can be used to verify borderline results. Horses often have low T4 levels secondary to EMS or PPID. Animals on anti-inflammatories, antibiotics or with chronic illness may have falsely decreased total T4. Animals given supplements containing kelp may have elevated results and show clinical signs of hyperthyroidism. Treatment is best monitored with a 4 to 6 hour post treatment T4 level, except for dogs with positive autoantibody tests which should be monitored using free T4 by dialysis. For further interpretation please see the interpretation on our webpage at https://ahdc.vet.cornell.edu/Sects/Endo/caninetestinfo.cfm or https://ahdc.vet.cornell.edu/Sects/Endo/equinetestinfo.cfm or https://ahdc.vet.cornell.edu/Sects/Endo/felinetestinfo.cfm

Effective December 1st, Anatomic Pathology will be implementing histopathology levels for histopathology submissions with the exception of hepatopathology and dermatopathology submissions, which are priced separately. Please go to https://bit.ly/3mDCvhM for a list of current histopathology levels and descriptions as well as updated pricing. Questions can be directed to pathologyservice@cornell.edu.

UNIVERSITY OF CALIFORNIA, DAVIS

BERKELEY • DAVIS • IRVINE • LOS ANGELES • RIVERSIDE • SAN DIEGO • SAN FRANCISCO SANTA BARBARA • SANTA CRUZ

CALIFORNIA ANIMAL HEALTH & FOOD SAFETY
LABORATORY SYSTEM
P.O. BOX 1770
DAVIS, CALIFORNIA 95617

PHONE: (530) 752-8700
FAX: (530) 752-6253

1/21/2022

CAHFS-San Bernadino
105 W. Central Ave
San Bernadino, CA 92408

Sample ID:	S2110265
Location:	San Bernadino
Date Received:	2021-12-09
Date Taken:	2021-12-06
Laboratory No.:	EACL-211209-20
Sample Matrices:	Post-Mortem Blood, Urine, Aqueous Humor

INVESTIGATION: Post Mortem Analysis

The samples were analyzed by Liquid Chromatography - Mass Spectrometry and Enzyme Linked Immunosorbent Analysis for the presence exogenous substances. The results from the screening analysis are provided below:

Post-Mortem Blood:	Furosemide and Omeprazole Sulfide were detected at screening.
Urine:	Furosemide and Omeprazole Sulfide were detected at screening.
Aqueous Humor:	No exogenous substances were detected

Confirmation analysis was not performed unless otherwise indicated. If you have any questions or require additional information, please don't hesitate to contact me.

The remainder of the original sample will be stored at the Maddy Lab pending permission from the client for disposal.

Sincerely,

Benjamin Moeller, PhD DABT
Assistant Professor
University of California – Davis

Necropsy gross photos (per J.A.R.)

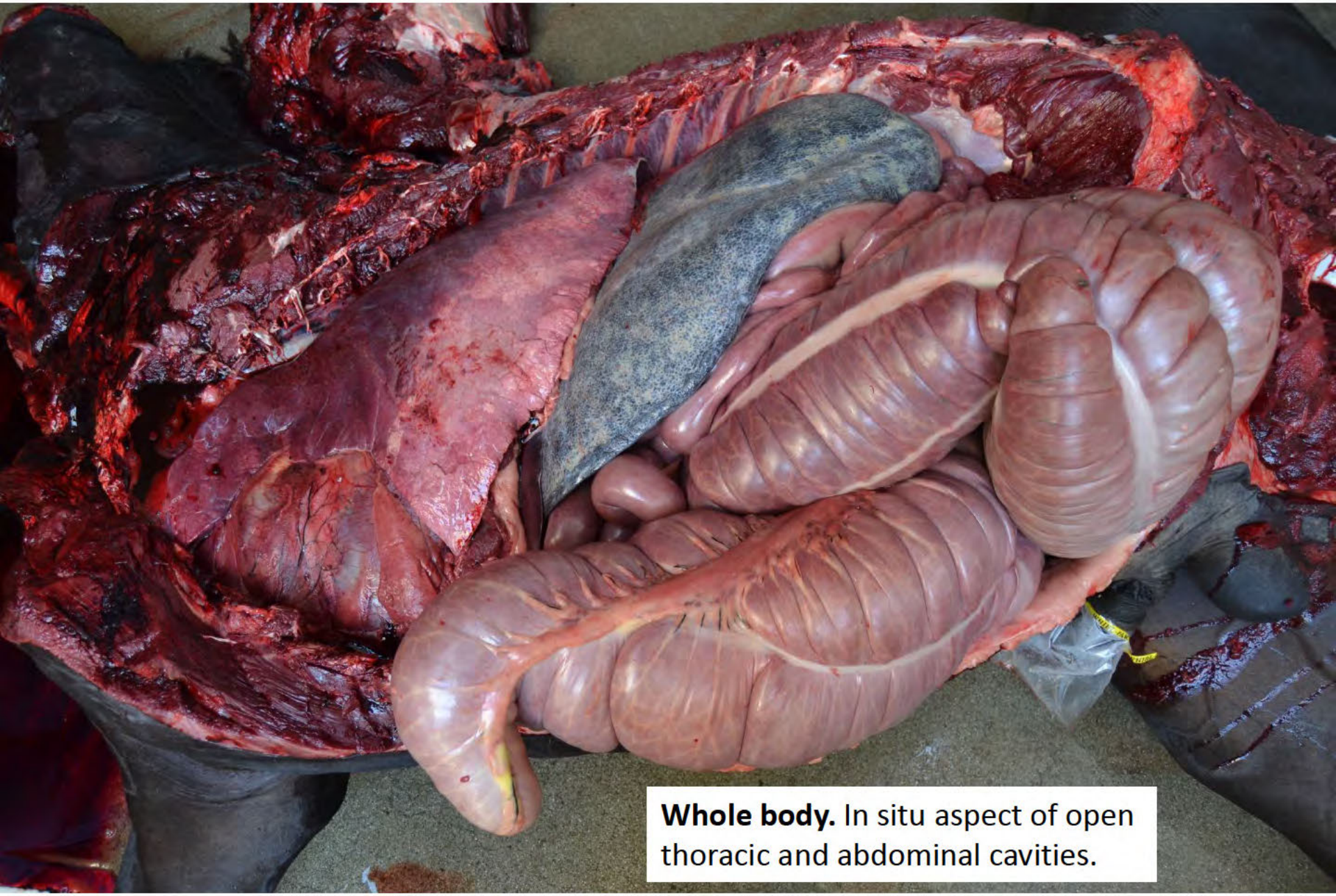

Whole body. In situ aspect of open thoracic and abdominal cavities.

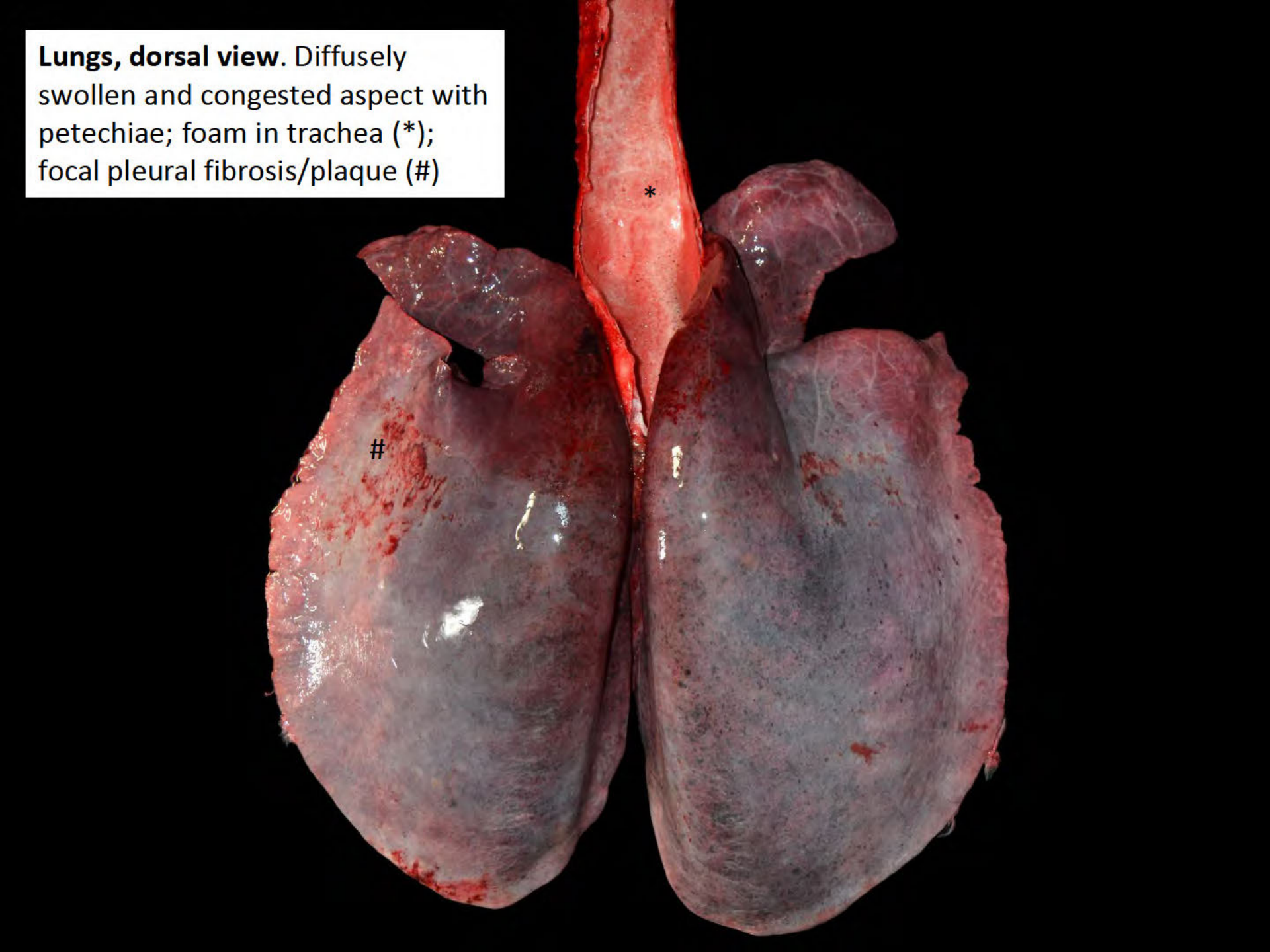

Lungs, dorsal view. Diffusely swollen and congested aspect with petechiae; foam in trachea (*); focal pleural fibrosis/plaque (#)

Right lung, close-up. Petechiae

Left lung, close-up. Mild pleural fibrosis

Lung, cut section. Regionally extensive congested area

Thymus. Petechiae

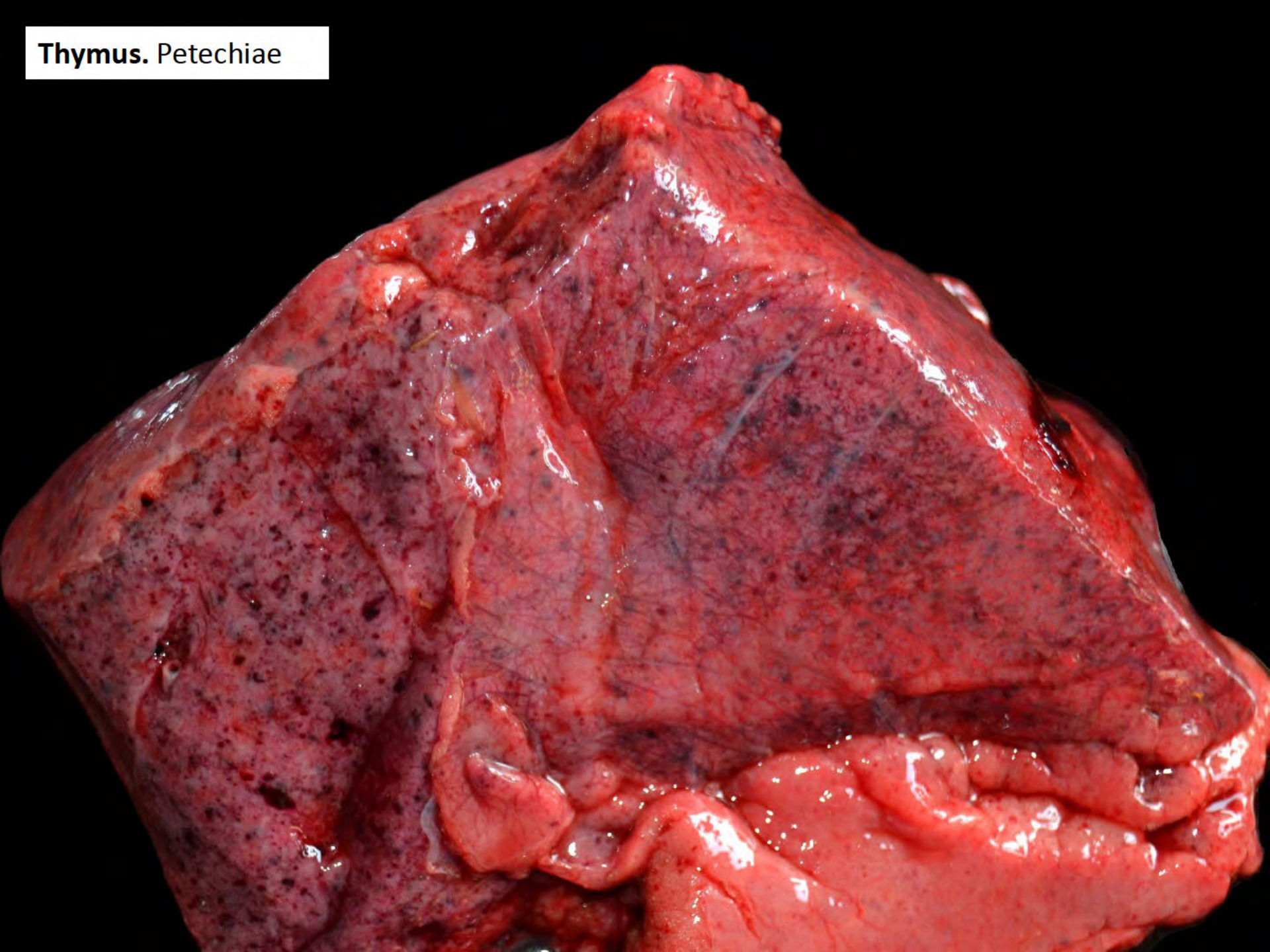

Tracheobronchial lymph node. Congestion

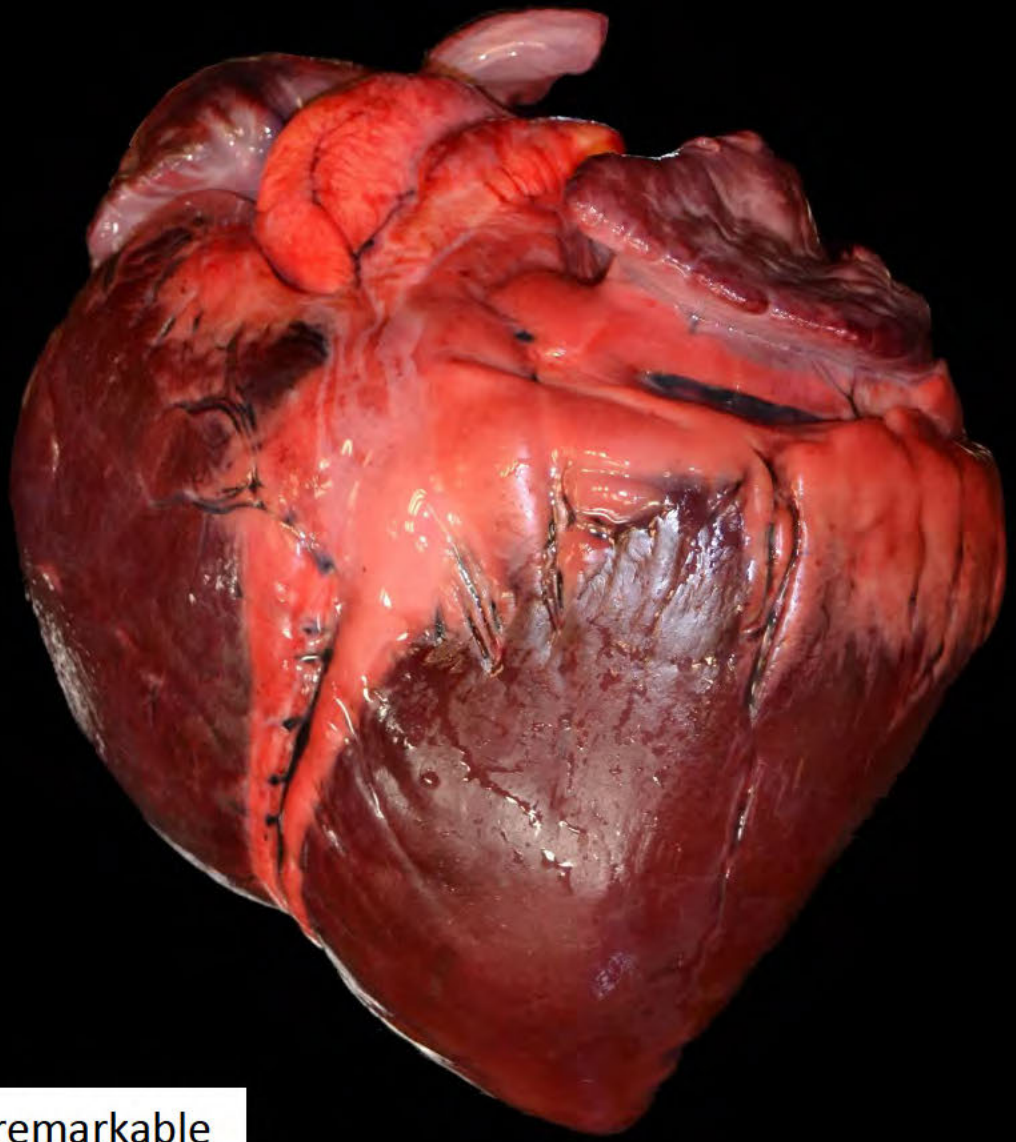

Heart. Grossly unremarkable

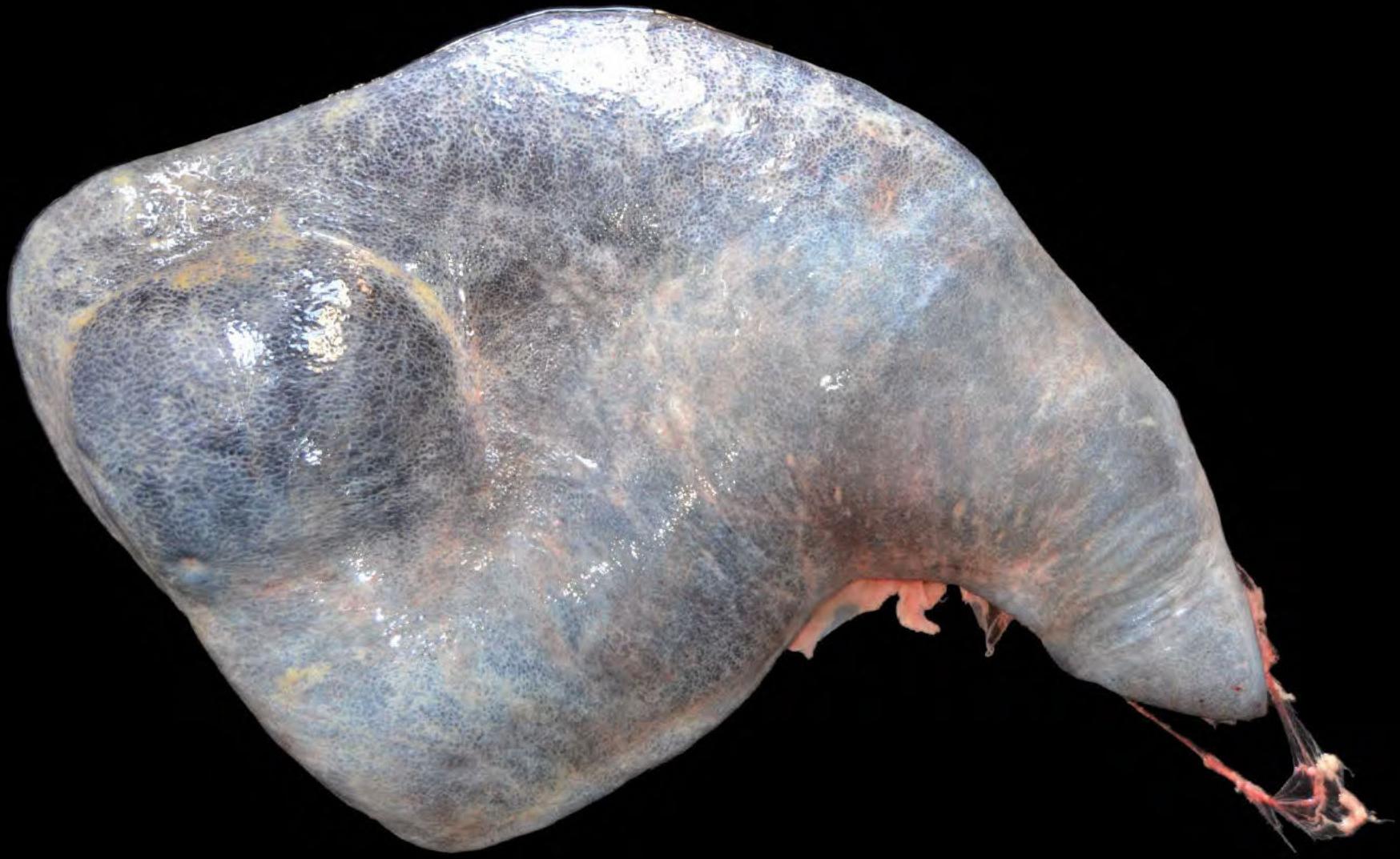

Spleen. Splenomegaly and congestion

Liver. Mild fibrous tags on the capsule of the right lobe (*)


Kidney. Corticomedullary congestion

Stomach. Mild congestion of glandular mucosa

Cecum, colon. Contents

Musculoskeletal exam gross photos (per M.A.S)

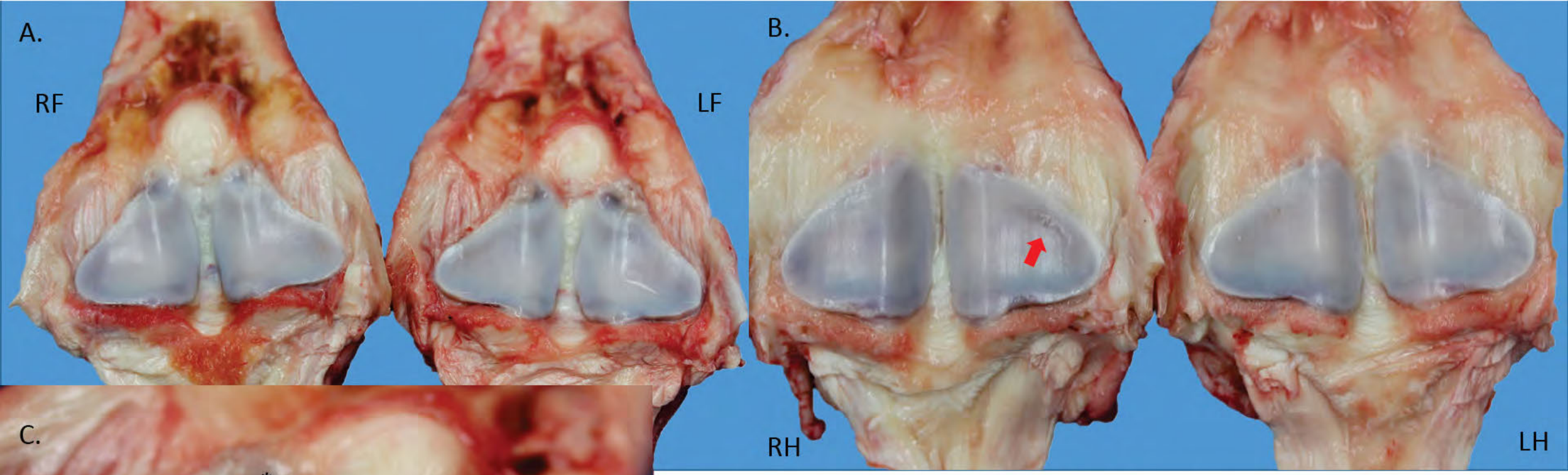

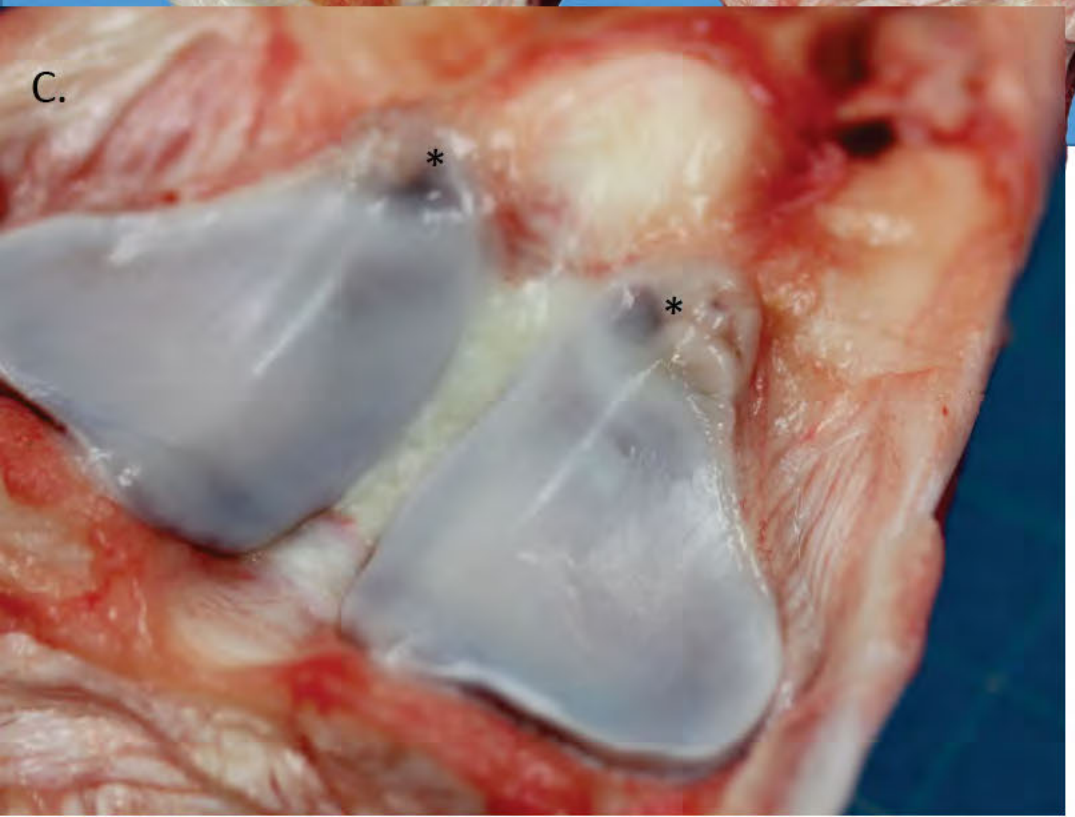

A. Proximal sesamoid bones (PSBs) from forelimbs with biaxial apical and basilar enthesophytosis, and multifocal/regionally extensive dark blue discoloration of the cartilage along the articular margins
B. PSBs from hindlimbs with biaxial apical and basilar enthesophytosis, regionally extensive, dark blue discoloration of the cartilage along the articular margins, and linear cartilage indentation accompanied by superficial cartilage loss along the abaxial margin of medial PSB in RH (red arrow)
C. Close-up on left front PSBs with distinct apical enthesophytes (*).

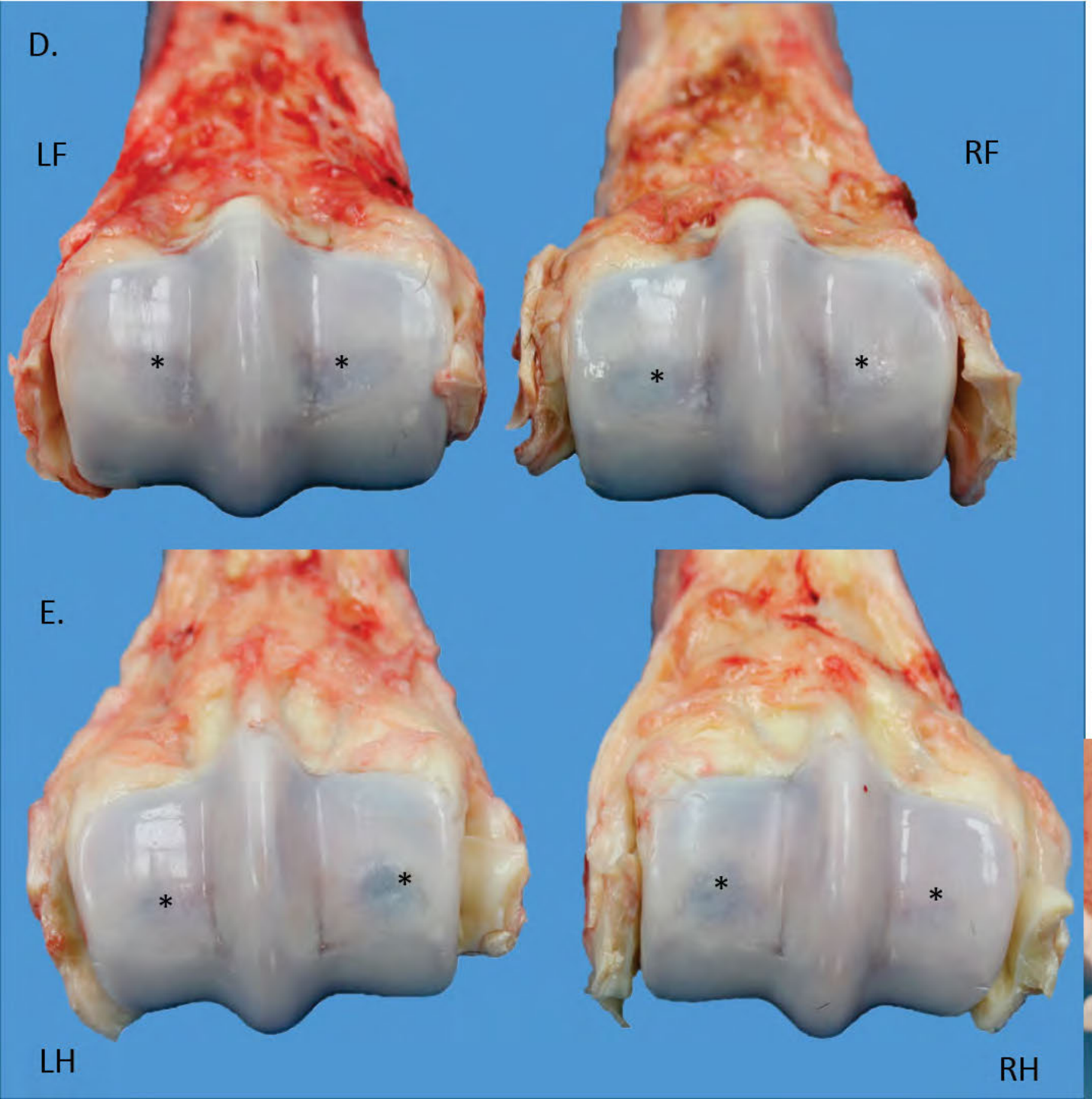

D. & E. Distal articular surfaces, views on palmar/plantar aspects of MCIII/MTIII- all 4 cannon bones are affected by palmar (D)/plantar (E) osteochondral disease (POD) (*) with medial condyle being more affected in each limb

F. & G. Longitudinal sections of medial condyles of both MTIIIs revealing the extent and severity of POD lesions

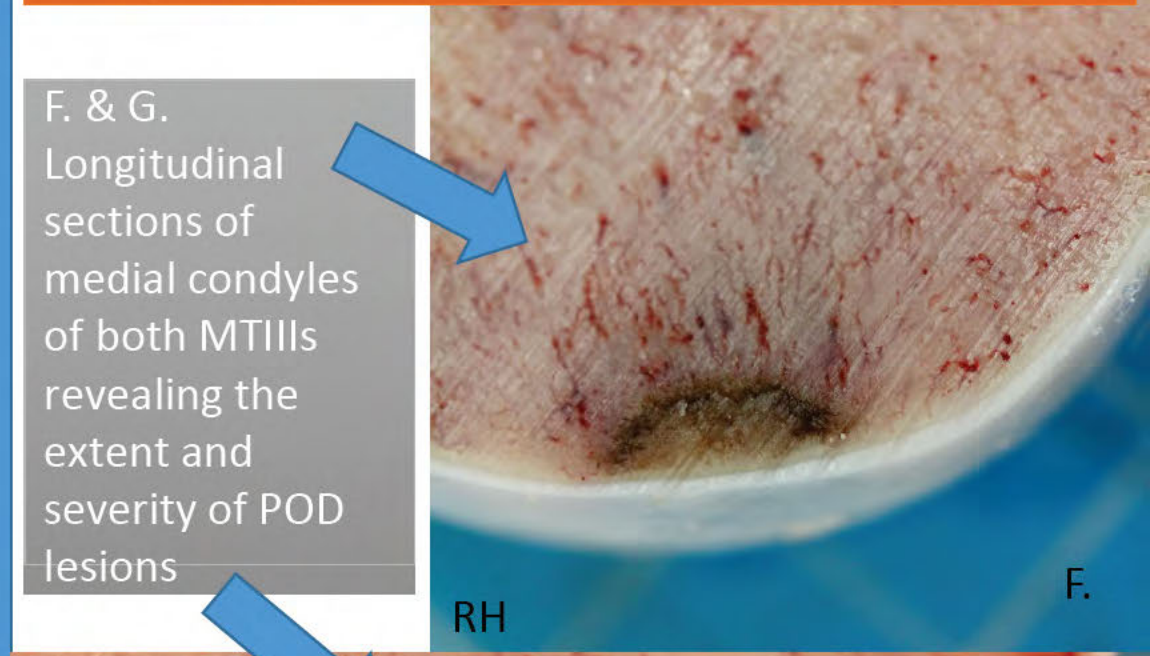

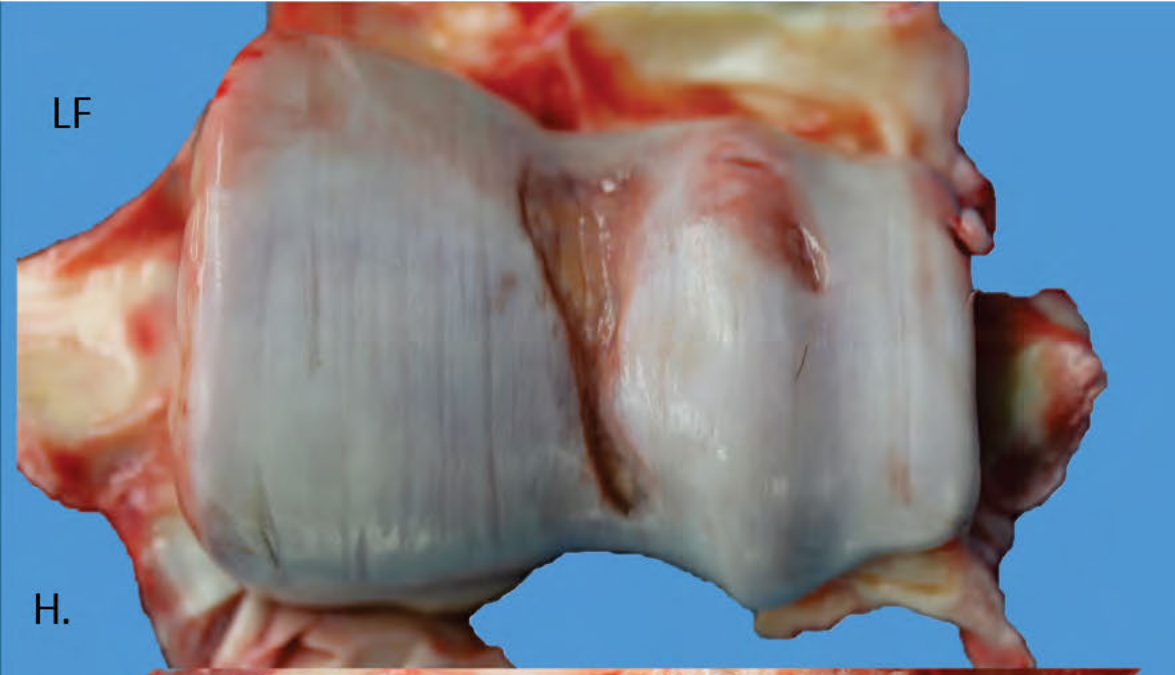

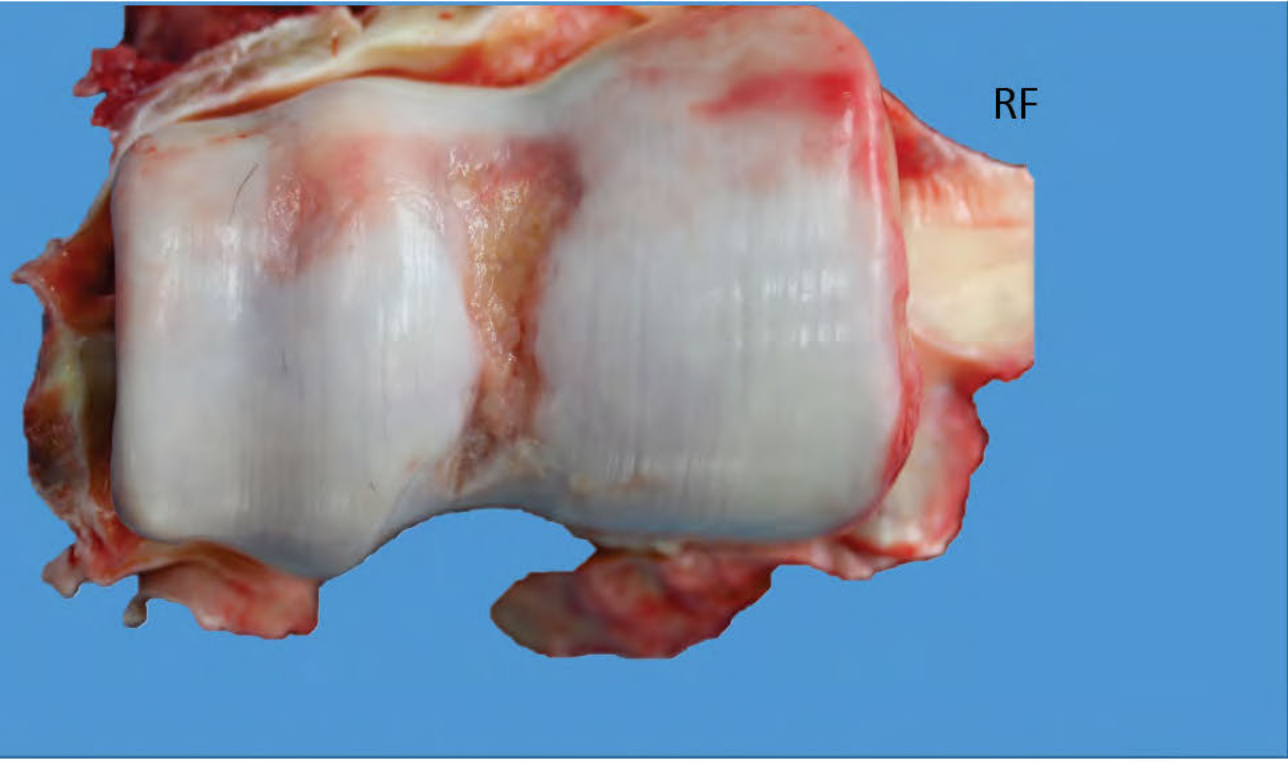

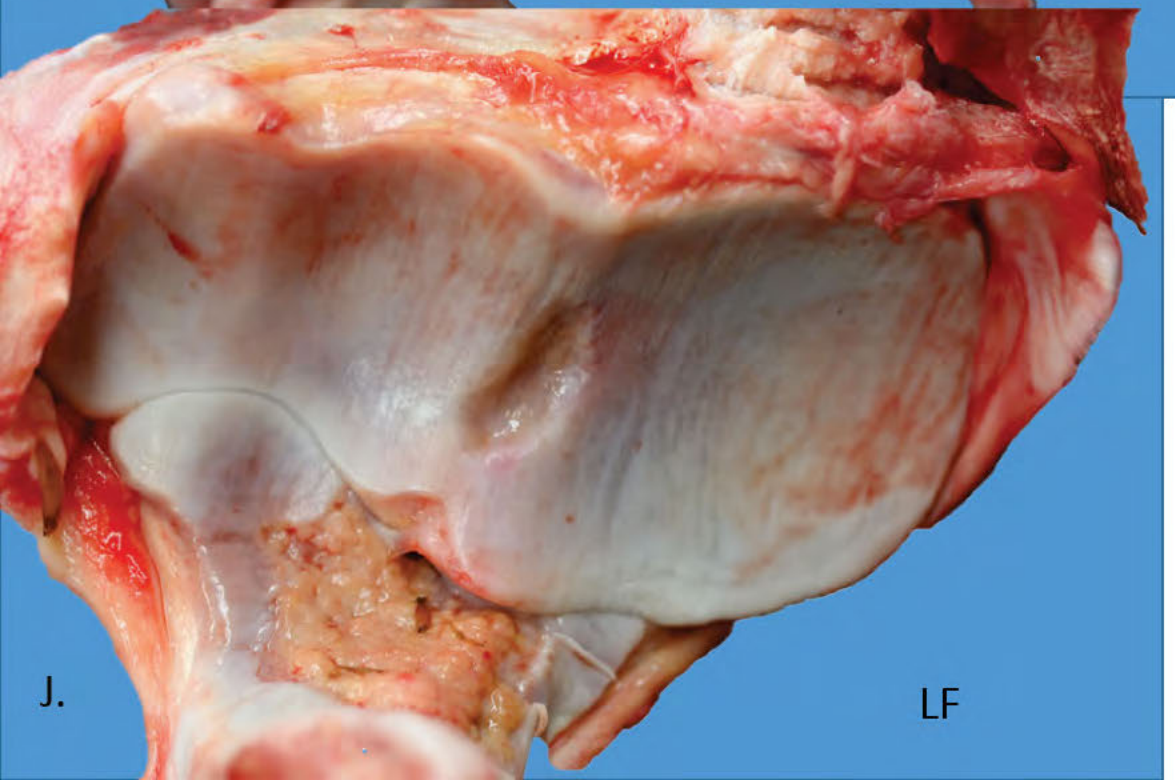

H, I, J. Severe scoring lines are present on the distal articular surfaces of both humeri (H, I) and proximal articular surfaces of left radius (J).

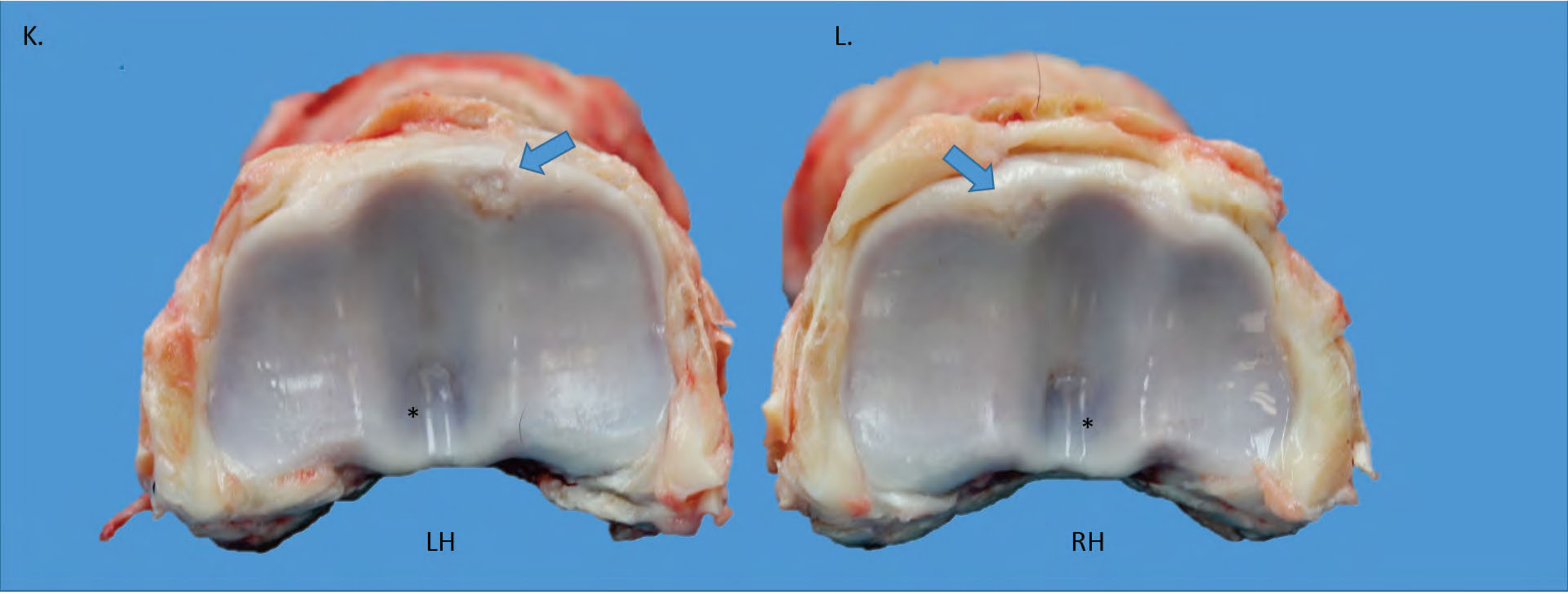

K, L. Proximal articular surface of P1s from hindlimbs with bilateral, focal, blue discoloration of the cartilage of intermediate groove (*) and bilateral focal cartilage loss of the dorsomedial aspect of articular margin (blue arrows)

M. Grant Maxie, DVM, PhD, Diplomate ACVP

University of Guelph (retired)

[redacted]

Puslinch, Ontario N0B 2J0 Canada

[redacted]

H: [redacted]

C: [redacted]

Subject: Review of autopsy report for CAHFS Accession S2110265

I was asked by Dr. John Pascoe to review the autopsy report on case S2110265, Medina Spirit, and I am pleased to do so.

I was provided with preliminary version 3 of the case report, including ancillary test reports and gross photographs. As well, I received a file of 76 Olympus digital images of histology slides for review.

The gross images are excellent, as are the scanned images of the histology slides.

I reviewed the preliminary case report and the digital histologic images. The samples taken, tests conducted, and interpretations are appropriate. The histologic observations are accurate, and I have nothing to add.

Cases of sudden unexpected death in racehorses are frustrating to deal with, and frequently remain unresolved, as in this case. Without monitoring of cardiac rhythm in vivo (e.g., by Holter monitoring), cardiac electrical activity remains unknown. Minor lesions of myocarditis ("very rare mononuclear infiltrates" in this case) or fibrosis (as in the Swale syndrome) may be the source of electrical instability and dysrhythmia, but such comments are speculative in postmortem cases. Marked acute pulmonary congestion and edema in this case is consistent with acute heart failure. Various other lesions noted are incidental.

I agree with the final diagnosis of "Cause of death: undetermined; sudden cardiorespiratory arrest/ cardiac failure suspected."

G. Maxie

February 9, 2022

University of Kentucky
College of Agriculture, Food & Environment
Department of Veterinary Science
Veterinary Diagnostic Laboratory

To Whom It May Concern:

On February 7, 2022 I reviewed gross photographs, digital histologic slides, and the postmortem report for the Thoroughbred Medina Spirit, CAHFS accession number S2110265. In total, there were 13 photographs of the viscera, 12 photographs of the skeletal system, and 76 scanned slides, including routine sections and special stains.

Histologic lesions in the heart were minimal and scattered, including rare aggregates of inflammatory cells, and rare hypercontraction bands. In my experience, the minimal degree of myocardial inflammation in this case can be found both in Thoroughbred horses in active race training that die for reasons other than sudden death, and in cases of sudden death. Therefore, significance cannot be attributed to this minimal degree of inflammation.

There was significant pulmonary edema and congestion, with a mild degree of hemorrhage. These findings are common in cases of sudden death, and do not rule-in nor rule-out a particular cause.

Additional findings in the viscera are within the expected range for a Thoroughbred horse in race training.

In summary, after review of the material presented, including results of ancillary tests (bacteriology, clinical pathology, toxicology, and endocrinology), I agree with the conclusion of sudden death of undetermined etiology.

Sincerely,

Laura A. Kennedy DVM, Dipl ACVP

Associate Professor

University of Kentucky Veterinary Diagnostic Laboratory